

Topological False Positives in Sciatic Localization: A Bayesian Failure Analysis of a 'Spine-First' Algorithm

Chi-Ming Chiang, MD, PhD^{1,2*}

¹Center for General Education, Chung Yuan Christian University, No. 200, Zhongbei Rd., Zhongli Dist., 320 Taoyuan, Taiwan, Republic of China.

²Department of Orthopedics, National Yang Ming Chiao Tung University Hospital, No. 169, Xiaoshe Rd., 260 Yilan, Taiwan, Republic of China.

Correspondence

Chi-Ming Chiang, MD, PhD

Center for General Education, Chung Yuan Christian University, No. 200, Zhongbei Rd., Zhongli Dist., 320 Taoyuan, Taiwan, Republic of China.

Received Date: 02 December 2025

Revised Date: 29 December 2025

Accepted Date: 25 January 2026

Publication Date: 06 February 2026

Copyright

© 2026 CME Online Library. This is an open-access article distributed under the terms of the Creative Commons Attribution 4.0 International license.



ABSTRACT

Background: Sciatica is commonly attributed to lumbar radiculopathy; extra-spinal causes in the deep gluteal space are frequently overlooked, particularly after otherwise successful lumbar surgery. **Computational Error:** Contemporary spine surgery often operates on a deterministic heuristic: structural pathology dictates clinical presentation. However, in the aging spine, structural pathology is statistically ubiquitous, creating a "High-Noise Environment. **Logic Trace:** The initial surgeon fell into a "Base Rate Neglect" trap, conflating the high prevalence of asymptomatic spondylolisthesis (Background Noise) with the active pain generator. The "Null Result" of the spinal fusion forced a Bayesian Update of the diagnostic probability distribution. **The Solution:** High-resolution MR neurography identified the true high-entropy signal: a T2-hyperintense piriformis muscle.

Conclusion: "Failed Back Surgery Syndrome" is often a misnomer for "Failed Algorithm Syndrome." We propose a logic-gate protocol based on First-Principles Signal Tracing to mathematically decouple incidental spinal noise from extra-spinal entrapment.

KEYWORDS

Bayesian diagnosis, Failed Back Surgery Syndrome, Piriformis syndrome, Signal-to-noise ratio, Topological error.

INTRODUCTION

Sciatica is often investigated through a spine-first lens, where imaging readily identifies disc pathology or foraminal stenosis. However, extra-spinal causes—most notably entrapment of the sciatic nerve within the deep gluteal space—are clinically important mimics. Piriformis syndrome (within the spectrum of deep gluteal syndrome) can reproduce pain patterns and neurodynamic symptoms typically attributed to lumbar radiculopathy. Pelvic MRI is the modality of choice to survey this corridor; characteristic findings include piriformis enlargement and T2/STIR hyperintensity reflecting edema or myofascial inflammation. High-resolution MR neurography can further depict signal change and caliber variation of the sciatic nerve proximal to the greater sciatic foramen. We present a patient with persistent sciatica after L4/5 surgery in whom pelvic MRI disclosed a T2-bright asymmetrical piriformis, underscoring the need for a dual-axis evaluation that considers both spinal and extra-spinal corridors of nerve

compression.

CASE PRESENTATION

A middle-aged patient presented with left-sided buttock and posterior thigh pain consistent with sciatica. Pre-operative lumbar imaging showed L4/5 spondylolisthesis with nerve root compromise, and decompression/fixation was performed. Post-operatively, symptoms persisted without focal motor deficit. Physical examination highlighted deep gluteal tenderness and reproduction of pain with hip flexion-adduction-internal rotation (FAIR) manoeuvre. Given discordant clinical-spinal findings, pelvic MRI was obtained. Coronal T2-weighted sequences with fat suppression demonstrated diffuse hyperintensity and mild hypertrophy of the left piriformis compared with the contralateral side, with subtle crowding of the greater sciatic foramen. No mass, abscess, or paralabral cysts were evident. These imaging features were consistent with piriformis syndrome within the spectrum of

deep gluteal entrapment.

Imaging Findings

Figure 1 Preoperative and postoperative radiographs of the lumbar spine. Lateral (left two panels) and anteroposterior (right panel) radiographs showing lumbar spondylolisthesis and degenerative disc disease at the L4-L5 level. Preoperative images (left) demonstrate segmental instability and disc space narrowing. Postoperative images (right) reveal restoration of lumbar alignment following L4-L5 transforaminal lumbar interbody fusion (TLIF) with pedicle screw fixation and interbody cage placement. The instrumentation is in satisfactory, with appropriate reduction of the spondylolisthesis and maintenance of disc height. Figures 2-4 are coronal T2/STIR pelvic MRI slices highlighting asymmetry and T2 hyperintensity of the left piriformis. Arrows and circular regioisof of interest (ROIs) mark the area of maximal signal change; schematic scale bars are included for orientation because DICOM pixel spacing was unavailable. Collectively, the images depict a clear extra-spinal pain generator concordant with the patient's persistent postoperative symptoms.

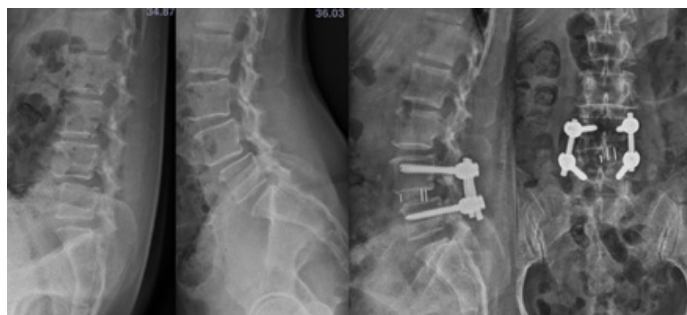

Figure 1: Pre- and postoperative radiographs of the lumbar spine showing L4-L5 spondylolisthesis treated with pedicle screw fixation and interbody fusion. Postoperative images demonstrate satisfactory reduction and fusion alignment.

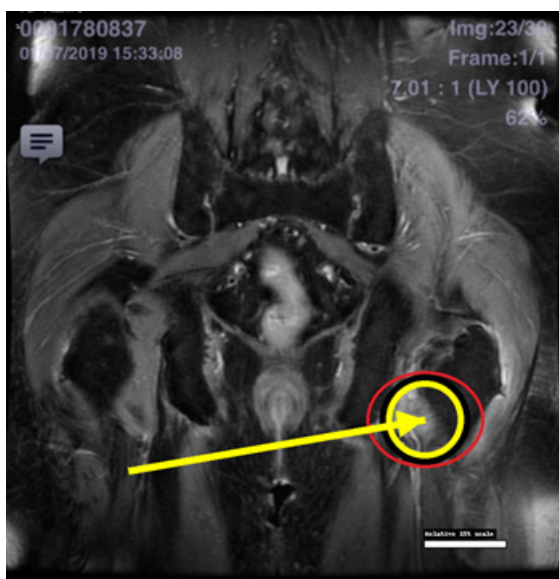


Figure 2: Coronal T2/STIR with surgeon-verified left piriformis ROI (yellow).

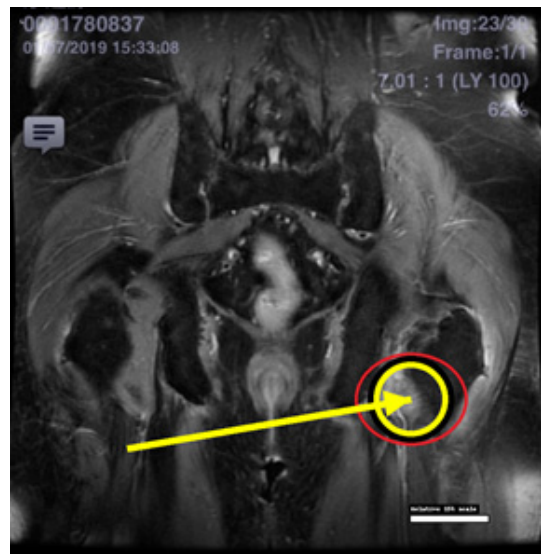


Figure 3: Coronal T2/STIR slice inferior to Figure 2 confirming persistent T2-bright signal within the left piriformis; the right side is normal.

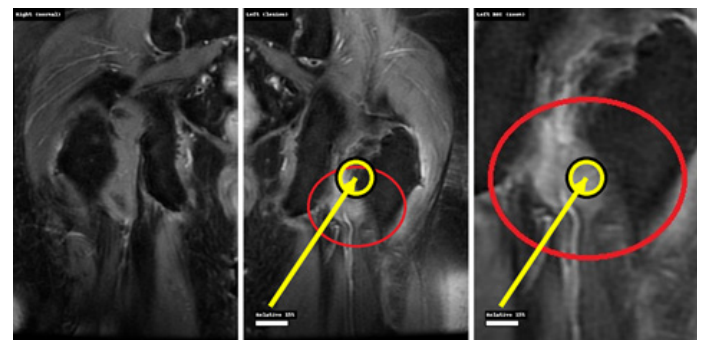


Figure 4: Additional coronal T2/STIR slice demonstrating the same asymmetric signal abnormality in the left piriformis. Schematic scale bars denote 15% of image width (pixel spacing unavailable).

Differential Diagnosis and Pitfalls

The principal differential includes recurrent or residual lumbar radiculopathy, hamstring origin tendinopathy, ischiofemoral impingement, obturator internus/externus pathology, and mass lesions of the sciatic notch. Diagnostic momentum toward the spine is a well-recognized pitfall once a plausible lumbar lesion is documented. In patients with persistent or recurrent sciatica after adequate decompression-or in those with atypical clinical patterns-pelvic MRI should be obtained early. MR neurography can add confidence by demonstrating signal abnormalities of the sciatic nerve itself near the piriformis plane. Where available, a diagnostic injection into or around the piriformis may both corroborate diagnosis and provide therapeutic relief [1-5].

Piriformis Syndrome vs L4/5 Radiculopathy: A Clinically Pragmatic Contrast

Both entities can provoke buttock-to-calf pain and straight-leg-raise irritability, which fosters diagnostic momentum toward the spine. However, piriformis syndrome typically

centers pain in the deep buttock with exacerbation during prolonged sitting or hip internal rotation and adduction (FAIR), often without a crisp dermatomal sensory loss or myotomal weakness. L4/5 radiculopathy more commonly generates dermatomal symptoms (e.g., L5 distribution to the lateral leg and dorsum of foot), reflex changes, and provocation with cough or Valsalva. Spinal MRI may reveal foraminal or lateral recess stenosis, but pelvic MRI is needed to visualize the piriformis and the subgluteal corridor. High-resolution MR neurography adds specificity by depicting T2 signal and caliber changes in the sciatic nerve proximal to the greater sciatic foramen. In this patient, figure-first inspection makes the contrast vivid: the right side is normal, the left piriformis is edematous and enlarged on three sequential coronal slices, and a structural spinal explanation for the persistent symptoms is unnecessary.

DISCUSSION

This case illustrates a recurrent diagnostic pitfall in sciatica: once a plausible lumbar abnormality is visualized, clinical reasoning may prematurely converge on a spine-only explanation. In older adults, radiographic degenerative findings-including spondylolisthesis-can be common in asymptomatic or community-dwelling populations, lowering their positive predictive value as pain generators and increasing the risk of false-positive localization [6-8]. Persistent symptoms after technically adequate lumbar decompression/fusion should therefore be treated as informative evidence that mandates a probabilistic reappraisal and systematic exploration of extra-spinal corridors of sciatic nerve entrapment, particularly within the deep gluteal space [1,2]. The Failure of the Greedy Algorithm: Using Stephen Wolfram's computational perspective, the standard orthopedic process behaves as a "Greedy Algorithm," locking onto the first visible local optimum (the slip) and missing the global solution.

Mathematical Formalism: The Bayesian Error

To rigorously deconstruct the diagnostic failure, we formalize the competing hypotheses using Bayes' theorem. Let H_S denote the hypothesis that the lumbar spine lesion at L4/5 is the dominant pain generator, and H_P denote the hypothesis that deep gluteal entrapment at the piriformis is the dominant pain generator. Let E denote the initial evidence: "sciatica with radiographic L4/5 spondylolisthesis."

The spine-first decision implicitly relied on the posterior probability $P(H_S|E)$, computed as: $P(H_S|E) = [P(E|H_S) \cdot P(H_S)] / P(E)$.

The critical error (base-rate neglect) is to over-weight $P(E|H_S)$ -the fact that spondylolisthesis can coexist with leg pain-while under-weighting the marginal likelihood $P(E)$, i.e., how frequently a slip is observed in the relevant population regardless of symptoms.

In asymptomatic individuals, the prevalence of imaging findings consistent with spinal degeneration increases

sharply with age; for spondylolisthesis, reported prevalence is approximately 23% at age 60 and continues to rise thereafter [6]. Population-based epidemiology likewise indicates age-dependent prevalence on the order of 20-30% in older adults, varying by sex and ethnicity [7,8]. In other words, the noise floor is high: observing a slip is not rare, and therefore its positive predictive value as the causal lesion is constrained.

The post-operative course introduced new evidence, E_{null} (null response), i.e., persistence of sciatica despite technically adequate fusion. Under a causal spinal model, the likelihood of E_{null} is comparatively low; accordingly, Bayesian updating drives the posterior toward: as $\text{Response} \rightarrow 0$, $P(H_S|E, E_{\text{null}}) \rightarrow 0$.

Simultaneously, pelvic MRI/MR neurography provided a higher-specificity signal, E_{MRI} : focal T2/STIR hyperintensity and mild enlargement of the piriformis with crowding of the greater sciatic foramen-a pragmatic imaging signature of deep gluteal syndrome [1,2]. Where available, MR neurography further increases specificity by demonstrating intrinsic sciatic nerve signal and caliber change near the piriformis plane [3]. In combination, these observations shift probability mass away from the high-prevalence spinal "background" and toward the low-noise extra-spinal node, making the diagnosis a mathematically coherent consequence of evidence accumulation rather than an opinion-driven reversal.

The "Greedy Algorithm" vs. "Signal Tracing" The Failure of a Greedy Algorithm

From a computational perspective, conventional orthopedic reasoning in degenerative disease can behave like a greedy algorithm: it searches for the first conspicuous abnormality (e.g., an L4/5 slip on radiographs) and locks onto it as the global solution. Greedy strategies are computationally efficient, but they are not guaranteed to find the global optimum when the search space is noisy and multimodal-conditions that typify the aging human musculoskeletal system. Wolfram's broader view of complex systems emphasizes that simple local rules can yield misleading global inferences when the underlying system is computationally irreducible [9].

Signal-to-Noise Ratio and the Type I Surgical Error

The core mistake can be reframed as a signal-to-noise ratio (SNR) miscalculation. The spinal slip represents a high-visibility signal on X-ray, but it also has high base-rate noise in older adults, yielding a low SNR. By contrast, piriformis edema (T2/STIR hyperintensity with asymmetry) is a high-contrast signal on pelvic MRI and is comparatively uncommon as an incidental finding, yielding a higher SNR in the context of buttock-dominant sciatica [1,2]. When the diagnostic system preferentially targets a high-noise spinal feature, it becomes vulnerable to a Type I error-a false-positive localization that can culminate in unnecessary or non-therapeutic surgery.

The Diagnostic Logic Gate (Check-Sum) to Prevent Spine-First False Positives

To reduce this Bayesian failure mode, we propose a simple logic-gate (check-sum) protocol that operationalizes prior-

probability adjustment. In a patient with sciatica plus radiographic spondylolisthesis, the first gate is positional biomechanics: is pain provoked more by sitting than standing? If yes, the biomechanical vector and symptom topology are more compatible with deep gluteal entrapment than with a purely spinal generator; this pattern is consistently emphasized in clinical descriptions and systematic reviews of piriformis syndrome [4,5]. In such a discordant presentation, pelvic MRI (and, when indicated, MR neurography) should be mandatory before any spine-modifying intervention.

Figure 5 schematizes this Bayesian decision process. A "spine-first" heuristic that treats visible degenerative changes as causal increases the risk of topological false positives in older adults; conversely, incorporating symptom-concordant priors, using null therapeutic response as formal evidence, and prioritizing high-specificity extra-spinal imaging can restore diagnostic calibration.

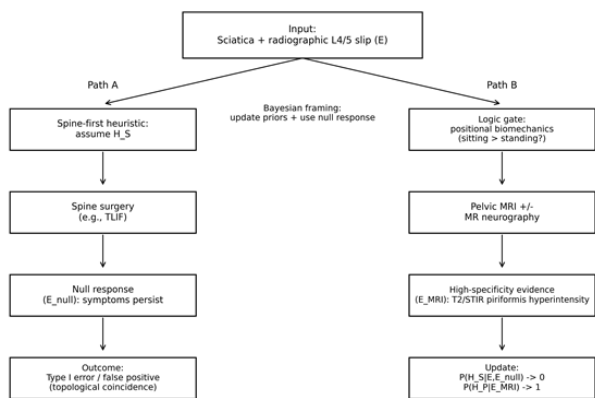


Figure 5: Bayesian Diagnostic Flowchart. (A) The flawed path: the "spine-first" heuristic relies on high prior plausibility of a spinal generator but fails to account for the high base rate of asymptomatic degenerative findings, leading to a false-positive surgery. (B) The signal-tracing path: a null response to surgery acts as formal evidence that collapses the spinal posterior, prompting evaluation of extra-spinal nodes. (C) Confirmation: pelvic MRI/MR neurography detects a high-SNR piriformis signal (H_P), supporting the true diagnosis.

Patient Consent and Ethical Compliance

Written informed consent for publication of clinical details and images was obtained. Institutional policies for case reports were followed.

REFERENCES

1. Petchprapa CN, Rosenberg ZS, Sconfienza LM, Cavalcanti CFA, La Rocca Vieira R, et al. MR imaging of entrapment neuropathies of the lower extremity. Radiographics. 2010; 30: 983-1000.
2. Hernando MF, Cerezal L, Pérez-Carro L, Abascal F, Canga A. Deep gluteal syndrome: anatomy, imaging, and management. Skeletal Radiol. 2015; 44: 919-934.
3. Chhabra A, Andreisek G, Soldatos T, Wang KC, Flammang AJ, et. MR neurography of the lumbosacral plexus and sciatic nerve. AJR Am J Roentgenol. 2012; 198: 357-364.

4. Fishman LM, Schaefer MP. Piriformis syndrome: diagnosis, treatment, and outcome-a 10-year study. Arch Phys Med Rehabil. 2002; 83: 295-301.
5. Hopayian K, Danielyan A. Four symptoms define piriformis syndrome: an updated systematic review of its clinical features. Eur J Orthop Surg Traumatol. 2018; 28: 155-164.
6. Brinjikji W, Luetmer PH, Comstock B, Bresnahan BW, Chen LE, et al. Systematic literature review of imaging features of spinal degeneration in asymptomatic populations. AJNR Am J Neuroradiol. 2015; 36: 811-816.
7. Wang YXJ, Kaplar Z, Deng M, Leung JCS. Lumbar degenerative spondylolisthesis epidemiology: a systematic review with a focus on gender-specific and age-specific prevalence. J Orthop Translat. 2016; 11: 39-52.
8. Denard PJ, Holton KF, Miller J, Fink HA, Kado DM, et al. Osteoporotic Fractures in Men (MrOS) Study Group. Lumbar spondylolisthesis among elderly men: prevalence, correlates, and progression. Spine (Phila Pa 1976). 2010; 35: 1072-1078.
9. Wolfram S. A New Kind of Science. Wolfram Media; 2002.